

# Guidelines for Clinical Conundrum Submissions



The aim of the clinical conundrum is to present a thought provoking case to the reader and allow in-depth discussion of the intricacies of the case presented. In particular, it is hoped that cases will challenge the reader to consider a dilemma, be it a diagnostic challenge or a treatment decision and to work through it to a logical conclusion. As a result, the clinical conundrum has become one of Companion's most successful and popular CPD features, providing thought provoking and engaging discussion of clinical problems.

## Case selection

The aim of the clinical conundrum is to present clinical scenarios which are encountered in small animal practice and discuss briefly any poignant features of the case. The conundrum can focus on the complete case management or one aspect of the case management in more detail.

Example of how a case may be used in a clinical conundrum:

- **A problem orientated approach to a challenging diagnosis.** In this instance the emphasis would be to challenge the reader to construct a problem list, consider relevant differential diagnoses and ultimately achieve a diagnosis based on the information gained during investigation. In this type of report emphasis should be focused on the rationale for choosing a given test and a logical approach to eliminating all other differential diagnoses.
- **Treatment or surgical dilemma.** In this type of case the diagnosis may have already been made or be relatively simple to reach. The focus of this type of conundrum would be to challenge the reader to decide how they would gather





the information to decide on a treatment plan and to select and justify choice of treatment based on the information obtained. This type of conundrum should not simply be a review of the literature, instead the emphasis should be placed on how the case was assessed and how these particular findings influence treatment choice

- *Conundrums that focus on one aspect of a complicated case.* Most suitable for a more focused evaluation of a single aspect of an individual case such as anaesthetic considerations and pre-anaesthesia stabilization for a clinical presentation or the subtleties of diagnostic imaging interpretation.

An unusual diagnosis although interesting does not necessarily mean that a case will be suitable to present as a clinical conundrum, as the final diagnosis is often one of the least important parts of the conundrum. Indeed, the cases which make the best conundrums discuss a presentation thoroughly, logically progress through a case and achieve a robust diagnosis or treatment choice. It is the dilemma regarding diagnostic or treatment progression which is important rather than the diagnosis in and of itself. The editorial team is more than happy to advise on the selection of cases for this feature and particularly welcome and encourage submissions from those in general practice.

## Style

Case reports should be structured to encourage the reader to consider different aspects of the case or diagnostic procedure as the clinical picture unfolds. This is easiest to achieve by posing questions which outline the author's thought processes at the time when the actual investigation was taking place and the answers to which dictate the next step in the clinical management of the case. Thus the reader gains an appreciation of the logical progression through the case and, just like in the clinical situation, is not aware of the end diagnosis or final decision at the outset.

Understandably this format is easier to follow for some cases and in some clinical disciplines than others. However, the format has already been successfully adapted to a variety of different scenarios and members of the editorial board are always willing to assist with the construction of a conundrum around a suitable case.

An example of how a clinical conundrum, in which the focus is achieving a final diagnosis, could be structured is outlined below. Depending on the type and focus of a conundrum the format will of course vary.

## Initial presentation information

A brief clinical history to include signalment, presentation and examination findings.

- *Question: Create a Problem list?*  
Answer: A short list summarizing the most important clinical findings.
- *Question: Consider the differential diagnosis for your problems. Can your differentials be prioritized based on the history and physical examination findings?*  
Answer: The author should outline their thought processes as if the case was in front of them. For example, 'evidence of stranguria and dysuria made the lower urinary tract the most likely source of the haematuria'.
- *Question: Construct a diagnostic/treatment plan*  
Answer: Should outline which tests and treatments are appropriate in particular why a given test/treatment was chosen. For example, 'a biochemistry profile was performed to assess for metabolic causes of seizures such as hypoglycemia and hypocalcaemia'. Any monitoring or ongoing treatments while tests are performed should also be outlined.

## Results of investigations

- *Question: How your interpretation of the test results help you refine your differential diagnosis?*  
Answer: The results should be interpreted and the relevance of new findings to case management and diagnosis discussed. The problem list and differential diagnosis list may be reviewed and amended if necessary.
- *The process of investigation, interpretation of results and evaluation of patient progression continues until a final diagnosis is reached.*
- *A brief summary of the final diagnosis and review of the pertinent points of the case and the literature conclude the conundrum.*

## Preparing a submission

In total, authors should aim for a piece of 1400–2000 words in length with a 1–5 illustrative pictures and, ideally, type the manuscript in MS Word, in Arial Font Size 11 with double line spacing. Although Companion has a less formal style compared with formal case reports colloquial language should be avoided. The animal should not be referred to by its name for example and progression through the case should not use dates for different examinations. Instead this should be Day 1, for initial presentation and so on, depending on progress. Companion uses the BSAVA style with the



–ize rather than –ise suffix. Any clinical data should be presented in SI units, further details of SI unit conversions can be found on the BSAVA website:

<https://www.bsava.com/Resources/Conversiontables.aspx>

## Illustrations

As high resolution images as possible should be submitted alongside the conundrum. We will be able to help format images where needed, so don't worry too much as to the file format. Images should not contain any identifying information (for example the owner or animals name, the referring practice etc.). Permission should be sort to include pictures of people, in any of the images supplied, prior to publication.

## References

Given that the emphasis of this feature is problem solving, references are not usually required unless they are integral to the problem solving involved. When specific literature is state (for example a study has shown that cats are much more intelligent than dogs) then the number reference system should be used where a superscript number is added in the appropriate place in the text, starting the numbering from 1. The bibliography of the work is arranged by the order in which the citations appear in the text. Companion will list the references online and within e-Companion, they are not printed in the text, so their use should be as limited as possible.

The reference list at the end of the submission should be set out as follows:

1. Staudte KL, Hopper BJ, Gibson NR *et al.* (2004) Use of ultrasonography to facilitate surgical removal of non-enteric foreign bodies in 17 dogs. *Journal of Small Animal Practice* **45**, 395–400

References to books should be listed as follows:


2. Ford RB (1995) Canine hyperlipidaemia. In: *Textbook of Veterinary Internal Medicine*. 4th edn. Eds SJ Ettinger and EC Feldman pp. 1414–1419. WB Saunders, Philadelphia

**Please note** that all journal names should be spelt out in full, that page spans are complete, and that publishers and their locations are given for books.

## Submitting a clinical conundrum

Please email articles for submission to **companion@bsava.com** providing illustrations as separate graphic files these can also be embedded within the text of a document as needed. An author picture (head and shoulders portrait style) should also accompany the submission in as high a resolution as possible and please state where you were working when you saw the case.

Following initial review for suitability and style, the editorial board will then forward submissions for peer review. Review time is dependent on reviewer availability but it is intended that submissions be reviewed within 6–8 weeks from submission. An honorarium (currently £150) is payable on final acceptance of the article, provision of all figures/pictures in a suitable format and submission of an invoice.

The editorial team is more than happy to advise on the selection of cases for this feature, the construction of a conundrum around a suitable case and the refining of submitted work. If you have an idea for a conundrum but aren't sure how to proceed please do contact us at **companion@bsava.com**. 

**Examples of previous  
Clinical Conundrums follow...**



# Clinical conundrum



*Mathilde Granger of VET&PHYSIO and BVR SMA committee member invites Companion readers to consider a lame Whippet.*



## VIDEO CONTENT

Make sure you download the app version or visit the digital version of *Companion* online to benefit from the video content and high resolution X-rays accompanying this feature. If you have any questions about accessing your digital *Companion*, email [administration@bsava.com](mailto:administration@bsava.com) or call 01452 726700 during office hours and a member of our team will be happy to help.



A 3.5-year-old spayed female Whippet is presented for a right forelimb lameness of 6-weeks duration following trauma, with swelling of the right carpus. The lameness was described by the owner as consistent since the injury and has been poorly responsive to meloxicam and rest.

On clinical examination, the dog was well and in good body condition (2/5). The lameness was graded 4/10, improves with rest but rapidly worsens with exercise. Distant gait examination reveals that the stance phase of the stride of the right forelimb is shortened, with moderate hyperextension of the carpus during loading. Orthopaedic examination reveals a moderate effusion of the right carpus with pain on mobilization in flexion and extension. The effusion is more pronounced medially and caudally around the accessory carpal bone and in the carpal flexors' retinaculum. The rest of the orthopaedic examination is normal.

## Which anatomical structures could be affected?

The carpus is a complex joint made of seven bones arranged in two rows and supported by multiple short ligaments. The most movement occurs at the antebrachio-carpal joint between the radius and ulna, and the first row of carpal bones. Three major tendons support the joint on the palmar aspect: the ulnar carpal flexor; the superficial digital flexor; and the deep digital flexor tendons. Thus, injuries to the carpus comprise sprains, tendon injuries and fractures or luxations of one or multiple bones.

In the dog, the most common carpal injury is to the palmar ligaments and palmar fibrocartilage, leading to hyperextension of the carpus. This usually happens following a trauma (e.g. jump with inadequate landing). This is likely to represent what happened in this case.

The collateral ligaments can be damaged at the same time as a hyperextension injury. Injuries to the collateral ligaments alone are less common, described particularly in sport dogs subject to rapid changes in speed and direction, for example, in agility.

Intra-articular fractures of the small carpal bones are uncommon, mainly diagnosed on the radial carpal bone in racing Greyhounds and in active dogs such as Springer Spaniels.

Less common carpal injuries include chip fractures of the accessory carpal bone leading to loss of function of the ulnar carpal flexor tendon, and isolated strain of the ulnar carpal flexor tendon (or other tendons).

## Which diagnostic tests would you consider to make a diagnosis?

To assess the degree of ligamentous injury, a goniometric measurement of the joint range of movement (ROM) is performed, with comparison to the uninjured carpus.

The ROM was measured with a goniometer as 45 degrees in flexion and 220 degrees in extension

(+40 degrees hyperextension compared to neutral). The ROM was 0 degrees in varus (towards the midline) and 20 degrees valgus (away from the midline). The contralateral carpus was measured at 30 degrees in flexion and 200 degrees in extension (+20 degrees hyperextension compared to neutral) and with no lateral instability.

This suggests a partial sprain to the medial collateral ligament and to some palmar carpal ligaments. In order to confirm this suspicion and rule out further injuries or complications, plain (Figures 1 and 2) and stressed (Figures 3 and 4) radiographs were taken of both carpi, under general anaesthetic.

### What radiographically abnormalities are present?

The main findings on the right carpus are:

- Soft tissue swelling (joint effusion and soft tissue thickening)
- Small chip fragment from the ulnar carpal bone
- Mild hyperextension and widening of the medial intercarpal joint that could suggest damage to the medial collateral ligament and some palmar intercarpal ligaments
- Mild secondary degenerative joint disease
- Questionable medial displacement of the radial carpal bone (a degree of variability in the position of this bone compared with the radius has been described).

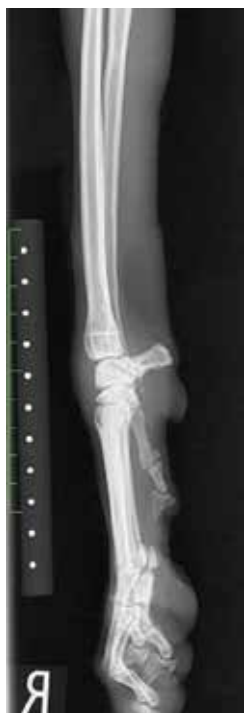

FIGURE 1: Mediolateral radiograph of the right carpus in a neutral position.

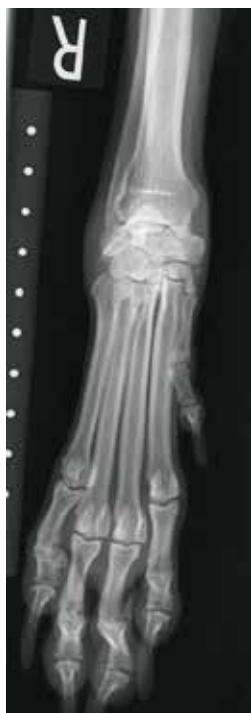

FIGURE 2: Dorsopalmar radiograph of the right carpus in a neutral position.

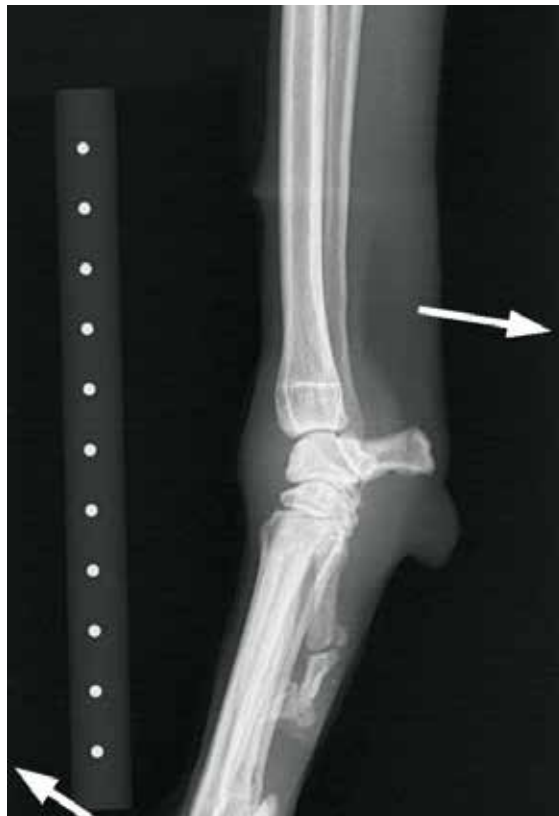

FIGURE 3: Mediolateral radiograph of the right carpus in a stressed extension position.

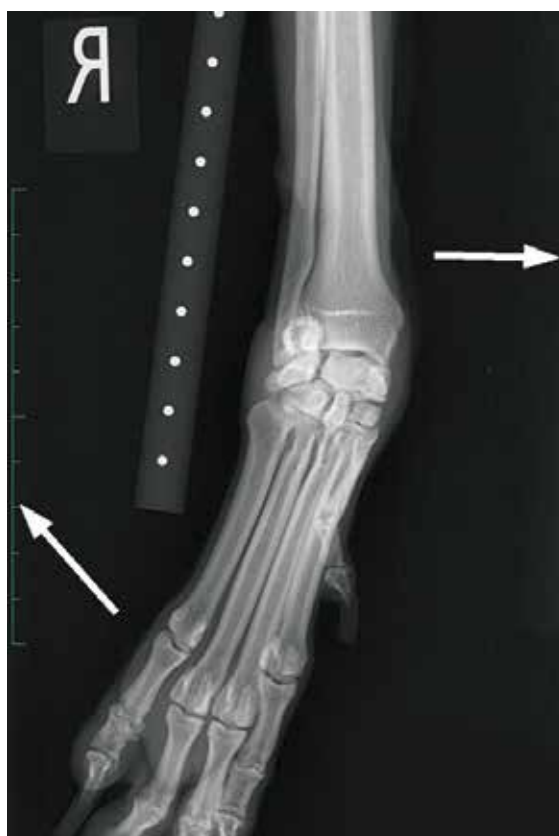

FIGURE 4: Dorsopalmar radiograph of the right carpus in a stressed valgus position.



These findings are consistent with a partial tear of the medial collateral ligament and some palmar intercarpal ligaments, as suspected clinically.

### How would you treat this injury?

Treatment options include either conservative management, rehabilitation with supportive brace or surgical intervention, mainly carpal arthrodesis. In this case, conservative management with rest and non-steroidal anti-inflammatory drugs (NSAIDs) had failed. Further management options include intensive rehabilitation with a supportive brace or surgical treatment.

The carpus is a very mobile joint during locomotion, with a movement of approximately 100 degrees from flexion to extension at walk. With the support of the carpal and digital flexor muscles, this joint has an important role of shock absorption and recoil, allowing for more efficient propulsion.

“ Treatment options include either conservative management, rehabilitation with supportive brace or surgical intervention, mainly carpal arthrodesis. ”

Rehabilitation with a supportive brace makes it possible to preserve this function, without further strain on the damaged ligaments. This patient is a small, light, well-muscled sighthound, thereby increasing the chances of a good outcome with this management option. However, there is very little data in the veterinary literature regarding conservative management of carpal sprains, particularly in cases of hyperextension injuries and most textbooks recommend carpal arthrodesis.

In this case, the degree of hyperextension is close to 40 degrees, and there may be a small intercarpal ligament avulsion from the ulnar carpal bone, which suggests significant damage to several ligaments, potentially beyond natural repair. Furthermore, there are already signs of early degenerative joint disease. This increases the risk of persisting lameness, even if conservative management is successful in healing the ligaments and stabilizing the joint.

Surgical ligament repair in the carpal joint is rarely described in the dog, and is not really an option in this case due to the delay after the injury. Thus, the only surgical option is a carpal arthrodesis. With involvement of both the antebrachiocarpal joint (medial collateral ligament) and intercarpal joint, a pancarpal arthrodesis would be the preferred surgical option.

Pancarpal arthrodesis has a good success rate. A study found 83% of a group of 14 working dogs able to continue work after surgery.<sup>1</sup> However, it also bears a significant number of complications (up to 50% of cases), including infection, implant failure, fractures, and wound breakdown, which would be a serious risk in this case due to the fragile nature of the skin in this breed. This procedure also changes the kinematics of the forelimb drastically.

Therefore, rehabilitation with a carpal brace is preferred as the initial treatment option in this case. It was agreed between the owner, the orthopaedic surgeon and the rehabilitation team that arthrodesis would be performed if conservative management failed to improve the lameness within 6 weeks.

### How would you conduct a rehabilitation course for this injury?

The aims of the rehabilitation course in this case are, in chronological order:

1. Control the pain and inflammation of the carpus
2. Support the ligaments during the healing process
3. Improve the muscle mass and strength of the affected limb
4. Improve proprioception of the affected limb (throughout the rehabilitation course)
5. Gradual return to exercise.

Adequate support needs to be provided to avoid further stretch of the injured ligaments. Equally, it is now recognized that rigid fixation of a joint is detrimental to ligament healing, leading to thinning of the ligaments and weaker tensile strength of the repair. Rigid fixation may also lead to further joint damage, cartilage erosion and early onset of degenerative joint disease. Therefore, this patient was discharged with further NSAIDs (meloxicam) and a moderate support carpal brace. The brace was fitted to achieve 0 degrees hyperextension at stance.

The owner was instructed to remove the brace three times a day to perform passive range of movement exercises (PROM) in order to avoid ankylosis of the joint, particularly in flexion. Neuromuscular electrical stimulation (NMES) to the carpal flexor muscles (ulnar carpal flexor, deep digital flexor and superficial digital flexor) is prescribed to maximize the palmar support of the joint. The dog should be walked twice a day for 10 minutes on the lead (**Video 1**). For the following 6 weeks, the dog received weekly physiotherapy and weekly laser therapy to the affected ligaments.

### Follow-up

At the 4-week follow-up the dog was walking 15 minutes, three times a day without lameness and the joint swelling was reduced. The ROM in hyperextension was measured at 30 degrees. Mild skin abrasions under the dewclaw were present. This minor complication

was managed by adding extra padding material between the nail and the skin, as well as twice daily wound care by the owner. NMES was discontinued. Isometric and proprioception exercises were prescribed (standing on a wobble cushion), alongside a gradual increase in daily exercise. From this point onwards, the brace-wearing time is gradually reduced to exercise only (lead walks or in the garden).

At 8 weeks the dog was being walked 30–45 minutes, twice a day on the lead. Some joint fibrosis and crepitus were observed on carpal examination, with no sign of active inflammation. The ROM in hyperextension was 25 degrees, but limited to 60 degrees in flexion. A softer brace was fitted to allow a gradual return to full exercise. The owner was advised to continue with PROM to improve carpal flexion and given further strengthening exercises for the dog, such as standing on three legs.

At 12 weeks the dog was sound at all speeds and walking up to 1 hour daily, with regular off-lead exercise. NSAIDs were discontinued. A mild reduction of the ROM in flexion (50 degrees) was noted, but no instability in extension, valgus or varus was recorded.

A follow-up phone call to the owner at 6-months post-rehabilitation confirmed that the dog was sound with a normal exercise regime.

## Discussion

Ligaments are poorly vascularized structures that never fully heal to return to normal strength. Studies show that ligaments recover 50–70% of their original strength a year after injury.<sup>2</sup>

Sprains are usually classified according to the severity and to the localization of the ligament injury.

“With the progress of rehabilitation and external support devices, it becomes useful to assess the degree of instability in order to make the best treatment choice.”

- Grade 1: internal fibrous elongation without loss of function or instability
- Grade 2: partial tear of the ligamentous fibres with partial disruption and instability
- Grade 3: complete ligament rupture
- Grade 4: avulsion fracture leading to complete loss of ligamentous function and instability

Veterinary surgeons do not routinely characterize the degree of carpal sprain, maybe

because until recently, this did not affect the treatment choice. However, with the progress of rehabilitation and external support devices, it becomes useful to assess the degree of instability in order to make the best treatment choice. Indeed, if complete ruptures and luxations need to be treated surgically, partial sprains may respond well to appropriate support and rehabilitation.

Goniometric measurement of the ROM of the carpal joint has been validated in the dog. Thus, goniometry is a reliable tool to rate the degree of instability and to follow the progress during the course of rehabilitation.

A good knowledge of the phases of repair is necessary to tailor the rehabilitation to the stage of repair. Immediately after the injury haemorrhage occurs, followed by acute inflammation, leading to swelling and pain. After a few days, regeneration starts, mobilizing fibroblasts, myofibroblasts and early collagen deposition. This repair is weak and disorganized. During this phase, partial immobilization to avoid disruption of early repair is necessary. Physiotherapy modalities that enhance tissue repair may be beneficial as well, hence the use of laser therapy in this case. In the later stages, remodelling of the scar tissue occurs, with deposition of collagen type 1 and realignment, thereby increasing tensile strength. During this phase, remobilization, strengthening and proprioceptive training gradually allow a return to full function.

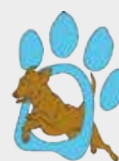While rest and NSAIDs are generally unsuccessful in managing carpal injuries, the recent development of rehabilitation and customized braces offers a genuine option to treat minor carpal instabilities conservatively. A study reported successful management of carpal medial or lateral collateral ligament injury with brace and rehabilitation, with return to sport in 11 out of 12 agility dogs.<sup>3</sup> To the author's knowledge, this is the first description of management of a carpal hyperextension injury and instability with brace and rehabilitation. ■



References and further reading are available online and in *e-Companion*.

### BVRSMA

The British Veterinary Rehabilitation and Sports Medicine Association (BVRSMA) is an affiliated group of the BSAVA and aims to provide continuing professional development for veterinary surgeons, physiotherapists and nurses with a specific interest in rehabilitation. All are welcome and for more information about becoming a member of BVRSMA visit [www.bvrsma.org.uk](http://www.bvrsma.org.uk).



# Clinical conundrum



*Harriet Hall, an Intern at Dick White Referrals, invites *Companion* readers to consider a jaundiced Jack Russell Terrier.*

## Clinical presentation

An 8-year-old male neutered Jack Russell Terrier was referred for investigations of intermittent aggression, weight loss, inappetence and elevated ALP, AST and bilirubin on biochemistry. The owners described aggression towards other dogs 12-months previously. This was attributed initially to orthopaedic pain, due to left hindlimb lameness. The patient was started on a gabapentin trial (12.5 mg/kg orally q12h). Gabapentin provided little improvement and the episodes of aggression became more frequent and unpredictable 2-months prior to referral. Gradual weight loss and inappetence were reported, biochemistry revealed elevated ALP (High – above the limit of the analyser), AST (581  $\mu\text{mol/L}$  (reference interval: 13–78)), and bilirubin (70.5  $\mu\text{mol/L}$  (reference interval: 0–16)); this prompted referral. The patient was vaccinated, wormed and had not travelled outside the UK.



On presentation, the patient was markedly jaundiced and the owners described an increase in drinking in addition to the history already mentioned. On clinical examination, the patient was quiet, alert and responsive; no cardiovascular, respiratory, musculoskeletal or neurological abnormalities were detected. Body condition score was 3/5, temperature was unremarkable (38.7°C), the pulse rate was 90 beats per minute and respiration rate was 24 breaths per minute. The abdomen was relaxed with no hepatomegaly palpable.

## Create a problem list based on the dog's history and examination

- Jaundice
- Polydipsia/polyuria
- Intermittent aggression/behavioural changes
- Weight loss
- Reduced appetite
- Dental disease, halitosis
- Possible intermittent left hindlimb lameness

## What would be your differentials from these problems?

- Jaundice
  - Pre-hepatic: haemolytic anaemia (such as immune-mediated haemolytic anaemia)
  - Hepatic:
    - Inflammatory: lymphocytic plasmacytic hepatitis, neutrophilic or histiocytic hepatitis
    - Neoplastic: lymphoma, hepatic carcinoma, haemangiosarcoma
    - Infectious such as leptospirosis, CAV-1 (adenovirus) or *clostridium* spp.
    - Toxicities: caprofen, trimethoprim-sulphate or copper.
  - Post-hepatic:
    - Functional: cholangitis – infectious/inflammatory
    - Physical: mucocoele, polyp, neoplastic, cholelithiasis and pancreatitis.
- Polydipsia/polyuria
  - Central diabetes insipidus
  - Nephrogenic diabetes insipidus:
    - Primary
    - Secondary: hepatic disease, hypokalaemia, hypercalcaemia, hyperthyroidism, hypoadrenocorticism, hyperadrenocorticism, pyelonephritis.
  - Osmotic: chronic kidney disease, diabetes mellitus

- Aggressive behaviour
  - Neurological:
    - Neoplastic such as lymphoma, meningioma etc.
    - Inflammatory/infectious such as GME, MUA, canine distemper, neosporosis, toxoplasmosis
    - Traumatic (head trauma).
  - Systemic: hepatic encephalopathy, pain associated conditions, hypothyroidism, hyperadrenocorticism, sensory deficits
  - Iatrogenic: glucocorticoids
  - Behavioural problems: separation anxiety, phobias such as to noise, territorial etc.

## What initial investigations would you consider?

Due to the history of jaundiced sclera, polydipsia and behavioural changes, and the initial blood test results from the referring vet, hepatic encephalopathy was suspected. Serum biochemistry, haematology, coagulation times, blood ammonia, urinalysis and abdominal ultrasonography were performed.

Haematology (Table 1) and blood smear analysis were performed to assess for anaemia; haemolytic anaemia is a differential diagnosis for jaundice and should be ruled out. Platelet levels were assessed for thrombocytopenia; this can be a complication of chronic liver disease which can limit diagnostic tests if present. Both were unremarkable as were coagulation times. The liver is responsible for the production of vitamin K dependent clotting factors, in severe liver disease, where hepatic dysfunction is suspected, this synthesis can be impaired and is indicated by a prolonged prothrombin time. Vitamin K is also a fat-soluble vitamin and is emulsified by bile acids. In cases of cholestasis when the biliary system is impaired, vitamin K absorption may be decreased, reducing activation of clotting factors. In combination these two affects can lead to a coagulopathy.

Biochemical evaluation was reassessed for any recent deterioration. This confirmed elevation in hepatobiliary parameters (ALT 339 IU/L, ALP 2828 IU/L, GGT 40 IU/L, AST 83 IU/L and bilirubin 97  $\mu$ mol/L) indicating hepatic or post hepatic disease given the absence of a concurrent anaemia in this patient (Table 2). Serum bile acid tests were not performed; these can be difficult to interpret in cholestasis. Cholestasis can be extrahepatic (where there is a mechanical problem with the duct system) or intrahepatic (where there are disturbances in bile formation due to hepatic disease). In an animal that has cholestasis, bile acids will not give you any additional information about the liver function; any interference with the transporters that take bile into the biliary system will result in an increased level of bile acids in the circulation. Hence, in cholestasis the bile acids will already be falsely elevated and so the ability to detect hepatic dysfunction or abnormal blood flow by measuring serum bile acids is masked.

Parameter	Result	Reference interval
RBC ( $\times 10^{12}/L$ )	6.44	5.5–8.5
Haemoglobin (g/dl)	15.7	12.0–18.0
HCT (L/L)	0.450	0.37–0.55
MCV (fl)	70.4	60.0–77.0
MCHC (g/dl)	34.6	30.0–38.0
MCH (pg)	24.4	19.5–25.5
Red cell distribution width (%)	12.40	12.0–13.2
White cell count ( $\times 10^9/L$ )	6.76	6.0–15.0
Neutrophils ( $\times 10^9/L$ )	4.46	3.0–11.5
Lymphocytes ( $\times 10^9/L$ )	1.36	1.0–4.8
Monocytes ( $\times 10^9/L$ )	0.34	0.2–1.4
Eosinophils ( $\times 10^9/L$ )	0.57	0.1–1.2
Basophils ( $\times 10^9/L$ )	0.03	0.0–0.1
Platelets ( $\times 10^9/L$ )	215	200–500
<b>Mean platelet volume (fl)</b>	<b>8.20</b>	<b>8.56–14.41</b>
White cell morphology	Unremarkable morphology	0–16
Red cell morphology	Normocytic and normochromic	0–70
Platelet morphology	Platelets are consistent with analyser count. No clumping seen.	3.8–7.0
Reticulocyte count ( $\times 10^9/L$ )	80.4	11–110
Reticulocyte haemoglobin (pg)	25.5	23.7–29.8
Reticulocyte (%)	1.25	0.0–1.5

**TABLE 1:** Haematology results (abnormal results are in bold). Sample quality: the serum was moderately haemolysed and mildly icteric.





Parameter	Result	Reference interval
Total protein (g/l)	59	54–77
Albumin (g/l)	26	25–40
Globulin (g/l)	33	23–45
Urea (mmol/l)	4.7	2.5–7.4
Creatinine (μmol/l)	61	40–145
Potassium (mmol/l)	3.8	3.4–5.6
Sodium (mmol/l)	148	139–154
Sodium:potassium ratio	38.9	>27.0
Chloride (mmol/l)	114	105–122
Calcium (mmol/l)	2.3	2.1–2.8
Inorganic phosphate (mmol/l)	1.0	0.60–1.40
<b>Glucose (mmol/l)</b>	<b>6.4</b>	<b>3.3–5.8</b>
<b>ALT (IU/l)</b>	<b>339</b>	<b>13–88</b>
<b>AST (IU/l)</b>	<b>83</b>	<b>13–60</b>
<b>ALP (IU/l)</b>	<b>2828</b>	<b>14–105</b>
<b>GGT (IU/l)</b>	<b>40</b>	<b>0–10</b>
<b>Bilirubin (μmol/l)</b>	<b>97</b>	<b>0–16</b>
<b>Blood ammonia (μmol/l)</b>	<b>80</b>	<b>0–70</b>
<b>Cholesterol (mmol/l)</b>	<b>2.7</b>	<b>3.8–7.0</b>
Triglyceride (mmol/l)	0.9	0.56–1.14
Lipase (DGGR) (IU/l)	14	8–120
<b>Creatine kinase (IU/l)</b>	<b>214</b>	<b>0–190</b>

**TABLE 2:** Biochemistry results (abnormal results are in bold). Sample quality: the serum was moderately haemolysed and mildly icteric.

Coagulation times	Result	Reference interval
Prothrombin time (s)	8.5	7.0–12.0
<b>APTT (s)</b>	<b>11.0</b>	<b>15.0–25.0</b>

**TABLE 3:** Coagulation times (abnormal results are in bold). Citrate sample quality: moderately haemolysed/icteric.

Fasting blood ammonia was mildly elevated (80 μmol/l) (Table 2) consistent with the suspicion of hepatic encephalopathy contributing to the behavioural changes. A high blood ammonia makes hepatic encephalopathy likely; a normal result does

not exclude it. Results should be interpreted considering other biochemical and clinical findings. In a healthy patient periportal hepatocytes convert ammonia to urea which is then excreted by the kidneys. Ammonia is also consumed via conversion of glutamate to glutamine when blood flows through the liver, decreasing ammonia in the systemic circulation. In the central nervous system (CNS), astrocyte cells act as buffers up-taking excess ammonia in hepatic encephalopathy. This alters astrocyte cells, causing swelling, leading to cerebral oedema. Chronic hepatic encephalopathy is more common in veterinary patients where cell swelling is progressive rather than acute and therefore the effects are less pronounced.<sup>1</sup> Ammonia rapidly increases with storage in whole blood and in separated plasma; when taking a blood sample for ammonia for an external lab you need to collect the blood in a cooled heparin tube, separate the plasma and freeze it immediately. The sample then needs to be transported to a laboratory on dry ice as the

“ When taking blood to determine ammonia levels at an external lab the sample should be collected into a cooled heparin tube, separate the plasma and freeze it immediately. ”

sample must remain frozen for the ammonia levels to be accurate. For in-house analysis, if you separate the heparinized plasma and put the plasma on dry ice without freezing it, the ammonia will be stable in the plasma for approximately 3 hours.

Evaluation of electrolytes was also unremarkable (Table 2). Hypokalaemia, hyponatraemia and alkalosis have been linked to potentiating hepatic encephalopathy in humans. Hyponatraemia potentiates cerebral oedema. Hypokalaemia reduces renal excretion of ammonia. Electrolytes in veterinary patients are presumed to have similar affects.<sup>1</sup>

As the patient was reported as polydipsic (potential polyuria with secondary polydipsia) a urinalysis was performed, which showed bilirubinuria (4+) which is consistent with the biochemistry results. Urine specific gravity was 1.032, which is concentrated, indicating that renal function was not impaired. Culture results were negative; otherwise the sample was unremarkable.

Abdominal ultrasonography was performed to assess the liver and other abdominal organs. It revealed microhepatica (although this can be challenging to assess with ultrasonography) with a normal echo texture. The gall bladder wall had several echogenic projections with peripheral mineralization

(Figure 1); these were considered mineralized polyps but could be cholelithiasis. The common bile duct was not distended, and the gall bladder was small making it hard to determine the contents accurately. The spleen had a 2 cm mixed echogenicity mass, deforming the capsule (Figure 2). A scant amount of free peritoneal fluid was evident although not of an adequate volume for sampling. The rest of the abdomen was unremarkable.

### How would you narrow your differential diagnosis based on these findings?

- Chronic hepatopathy resulting in hepatic dysfunction and hepatic encephalopathy.
- Cholestasis with or without cholelithiasis.
- A neoplastic process involving the liver cannot be ruled out based on a normal ultrasonographic appearance and a biopsy will enable a more accurate estimate of prognosis and identify more appropriate treatment options.
- The splenic nodule, although an incidental finding, may be benign such as a haematoma/haemangioma but could also be a metastatic neoplastic proliferation such as a haemangiosarcoma. Removal will allow histopathology and prevent the risk of rupture in the future.
- At this stage, based on the above results it was considered most likely that the patient had a post hepatic jaundice given the evidence of mineralization in the gall bladder. However, due to the lack of distension of the gall bladder and common bile duct a hepatic jaundice cannot be ruled out.

### What initial treatment steps would you take prior to further diagnostic tests?

- Treatment commenced with oral lactulose (1 mL/kg orally q8h) in case chronic hepatic encephalopathy was contributing to the behavioural changes. Lactulose enemas can be used in more acute cases. Enemas physically remove colonic contents removing a source of nitrogen from urease-producing bacteria. Most veterinary texts suggest 10 mL/kg as a retention enema with 3 parts lactulose to 7 parts warm water q4–8h.<sup>1,2</sup>
- Precautionary vitamin K1 (1 mg/kg s.c. q24h) was administered; absorption from the alimentary tract will continue to be impaired in cholestasis and the liver disease could progress despite supportive management, resulting in eventual changes in clotting parameters.
- Intravenous fluid therapy (IVFT) was started with 0.9% sodium chloride at maintenance (2 mL/kg/h). Lactate-containing fluids were avoided; animals with hepatic failure may struggle to metabolize this additive. Providing IVFT supports reduced intake, reduces ammonia concentrations by dilution and improves urinary output and therefore ammonia excretion.<sup>1</sup>

### What further investigations may be helpful?

- Inflated thoracic radiographs to assess for metastatic disease.

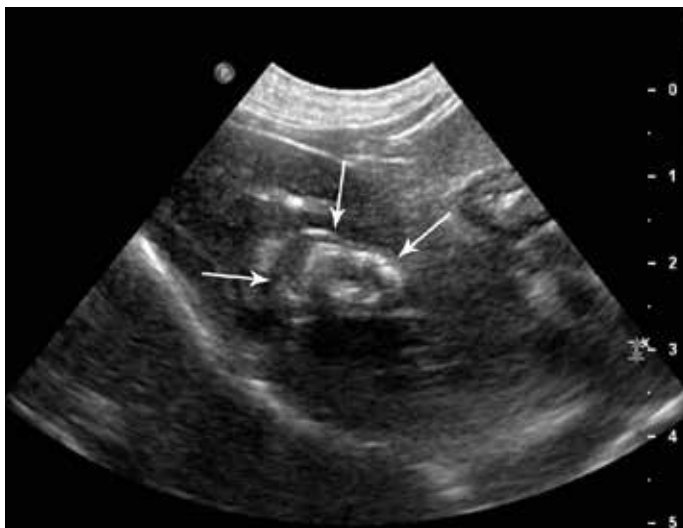

FIGURE 1: Ultrasonogram of the gall bladder showing echogenic projections and peripheral mineralization (white arrows).

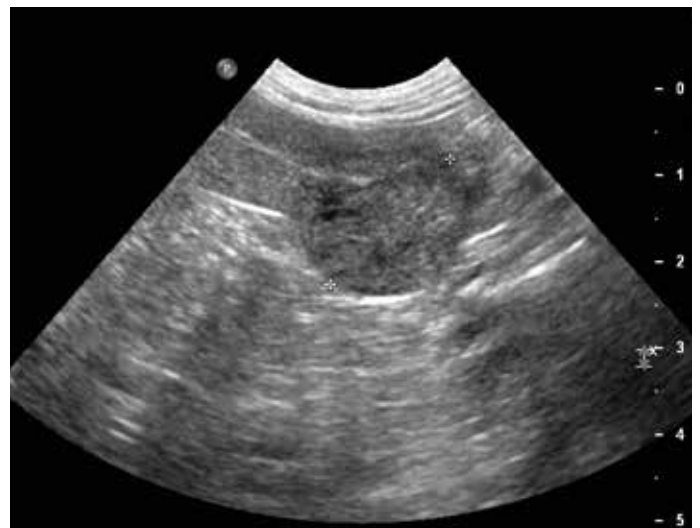

FIGURE 2: Ultrasonogram of the spleen showing a 2 cm mixed echogenicity nodule (marked by caliper measurement).



- Exploratory coeliotomy, to obtain hepatic biopsy samples and to perform cholecystectomy for histopathology and culture, and splenectomy for histopathology. To identify the cause of the hepatic disease and to determine a diagnosis for the splenic mass.

### Thoracic radiographs

- Three inflated chest radiographs were obtained perioperatively; left and right laterals and a dorsoventral view (Figure 3).
- Thoracic radiographs were consistent with a normal thorax with no evidence of metastatic disease.
- Mineralized bodies were superimposed over the hepatic parenchyma visible in all three radiographic views, consistent with the gall bladder wall mineralization reported on ultrasonography.

### At surgery

- Exploratory laparotomy was carried out. Hepatic biopsy specimens were taken with a view to identifying the cause of hepatic disease. Cholecystectomy was performed to treat the cholestasis; splenectomy to determine a diagnosis for the splenic nodule. The gall bladder was markedly thickened but not distended and was submitted for histopathology and culture; the spleen for histopathology. The patient recovered well.

- Postoperatively the patient received antibiotics with cefuroxime (20 mg/kg i.v. q8h), due to possible bile contamination post cholecystectomy. The patient was administered pain relief based on 4-hourly Glasgow pain scores using robenacoxib (2 mg/kg s.c. initially, then 1–2 mg/kg orally q24h), a lidocaine continuous rate infusion (40 µg/kg/min) and methadone (0.2 mg/kg q4h); gradually tapering as appropriate. Anti-emetic medication was provided using maropitant (1 mg/kg s.c. q24h) due to nausea. Vitamin K and lactulose continued at the perioperative dose until biochemistry was repeated prior to discharge.
- The patient was discharged, pending results, on cephalexin (20 mg/kg orally q12h for 7 days), robenacoxib (1–2 mg/kg orally q24h for 5 days) and lactulose (0.5 ml/kg q12h for 5 days).

### Results

The gall bladder samples confirmed chronic cholecystitis with intraluminal cholelithiasis. Bile, gall bladder tissue and liver tissue culture results were negative. The liver biopsies confirmed portal hepatitis (lymphoplasmacytic and histiocytic) with intrahepatic cholestasis; likely secondary to the gall bladder disease. The splenic mass was diagnosed as splenic hemangiosarcoma.

### The definitive diagnosis

Chronic cholecystitis with cholelithiasis and splenic hemangiosarcoma.

### What treatment options are available for this patient?

A hemangiosarcoma arises from the vascular endothelium and accounts for up to 2% of all tumours in dogs, of which splenic hemangiosarcoma represents 28–50%.<sup>3</sup> Splenic hemangiosarcoma is a relatively common, highly metastatic and rapidly fatal tumour in dogs.<sup>4</sup> At presentation, many patients already have macroscopic metastatic disease and those without have microscopic metastasis.<sup>4</sup>

Post splenectomy, chemotherapy is the adjunctive treatment of choice. The chemotherapy agents used for splenic hemangiosarcoma are metabolized in the liver; administration while the liver is compromised could result in high levels of chemotherapy agents in the systemic circulation through lack of metabolism and excretion, leading to toxic side effects. Equally, waiting to see if the hepatobiliary parameters recover before administration may reduce survival time. This, however, would also depend on the stage of the neoplastic disease. Many studies have reviewed staging schemes; the World Health Organization scheme evaluates stage I as hemangiosarcoma confined to the spleen, Stage II a splenic nodule that

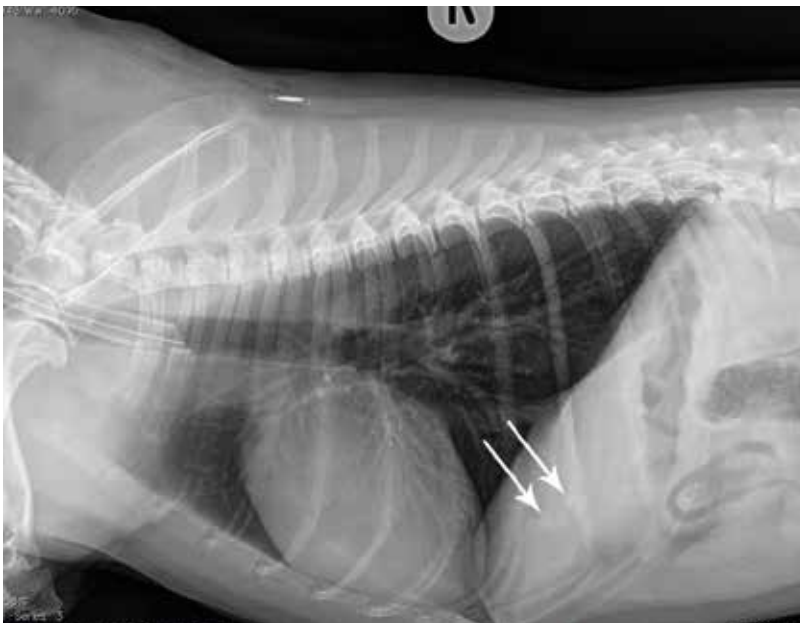


FIGURE 3: Normal right lateral thoracic radiograph. Mineralized bodies superimposed over hepatic parenchyma (white arrows).

has ruptured, or splenic nodule and lymph node metastasis and stage III as distant metastatic disease.

## Identifying the disease stage pre-surgery

This patient had no local or distant metastatic disease. The splenic mass was not ruptured, and the patient was presented for a concurrent condition. This patient was therefore in stage I of disease. Current research has largely been successful in showing that chemotherapy prolongs survival time in dogs, with longer survival times in those with stage I disease compared with stage II disease and stage III disease, respectively.<sup>3-5</sup> Chemotherapy should therefore be considered when discussing these patients with clients as a realistic option for adjunctive treatment postoperatively, while also considering comorbidities.

There are currently three main treatment options, the first of which would be a doxorubicin chemotherapy protocol; this is currently considered gold standard treatment in the management of hemangiosarcoma post splenectomy. Doxorubicin has been shown to improve survival time in patients with splenic

treatment;<sup>5,7</sup> however, this varies a lot between individuals and often correlates with staging at initial presentation. Around 6% of dogs survive for more than 1 year.<sup>8</sup>

Overall, whether adjunctive chemotherapy post splenectomy improves survival time compared to splenectomy alone still requires further research into more effective chemotherapy medications, protocols, combination therapies, earlier detection of disease and therefore the use of chemotherapy in earlier stages of the disease.<sup>4</sup> It is important to highlight that this patient was presented for a concurrent condition and the splenic hemangiosarcoma was initially an incidental finding thought most likely to be benign. Pursuing diagnostics to identify it resulted in earlier diagnosis, highlighting the importance of evaluating all diagnostic findings.

## Conclusion

The chronic cholecystitis with cholelithiasis would be expected to resolve postoperatively; this should have a positive prognosis. However, the incidental diagnosis of splenic hemangiosarcoma has a poor prognosis. On discharge, the hepatobiliary parameters were still significantly high, ideally a repeat biochemistry should be performed for monitoring of the hepatic disease and prior to discussing further treatment options such as chemotherapy. On this occasion a repeat biochemistry was not performed as the patient was doing well at home, showing no signs of jaundice or further aggression and the owners, having discussed prognosis, elected not to pursue further treatment for the hemangiosarcoma, happy with the option of splenectomy alone. 🐾

“Waiting to see if the hepatobiliary parameters recover before administration may reduce survival time.”

hemangiosarcoma in comparison to splenectomy alone. It is not curative but can be given by intravenous injection every 3 weeks with the average survival time in the literature for patients in stage I disease being 8.5 months (this varies between patients). There may be adverse clinical signs associated with this protocol, commonly vomiting and diarrhoea, less commonly bone marrow suppression.<sup>5,6</sup>

The second option would be a metronomic chemotherapy protocol using cyclophosphamide. This treatment is newer and therefore there is less research available documenting survival times, but it is thought to be effective in some canine patients. It is taken as an oral medication at home which may be preferable for some owners. The risk of side effects is low compared with that of doxorubicin, but the most common is sterile cystitis.<sup>5,6</sup>

The third option would be conservative monitoring. As chemotherapy has side effects and is not curative, some owners may elect to stop further treatment after splenectomy, especially in patients where there is a risk of toxicity due to concurrent disease. These patients must be carefully monitored at home for deterioration. Average survival times for dogs with this type of tumour are around 2-3 months with no further



References and further reading are available online and in *e-Companion*.



### CONTRIBUTE A CLINICAL CONUNDRUM

If you have an unusual or interesting case that you would like to share with your colleagues, please submit photographs and brief history, with relevant questions and a short but comprehensive explanation, in no more than 1500 words to [companion@bsava.com](mailto:companion@bsava.com).

All submissions will be peer-reviewed.

Guidelines for Clinical Conundrum submissions can be found online at [www.bsava.com/companion](http://www.bsava.com/companion).

# Clinical conundrum



*Amy Smith* presents the case of a cat with a soft cough and a dorsal swelling following a tooth extraction, seen during her final year at the University of Bristol. Amy graduated in July 2017 and is currently working for Viking Vets, an independent first-opinion small animal practice in Bristol.



A 16-year-old female neutered British Shorthair cat presented with a 3-day history of an occasional soft cough and a dorsal swelling at a post-procedural check following dental extractions in which her lower canine (404) was removed. She had previously been diagnosed with IRIS Stage 2 chronic kidney disease which was managed with a renal diet and daily subcutaneous fluids administered by the owner. She had a history of regular vomiting and had vomited that morning. During this episode the owner reported she appeared distressed, unable to breathe and vomit was passed through her nostrils. She had no previous history of respiratory disease.

On physical examination she was quiet, alert and responsive. Her respiratory rate was 28 breaths per minute and effort was normal. Lung auscultation was clear with no crackles or wheezes. No upper respiratory noise was detected. Her heart sounds were regular and unmuffled at 120 beats per minute and regular with good quality synchronous pulses. Her mucous membranes were pink with a capillary refill time of 1 second. Her nostrils appeared clear and no discharge was present. A non-painful swelling was present over her caudal neck and shoulder blades with crepitus when palpated. No wound was located and her temperature was normal.

Four hours later she had developed crepitant swelling extending bilaterally down her proximal forelimbs and appeared very uncomfortable. She made an occasional retching non-productive cough but was not dyspnoeic.

## Create a problem list based on the history and physical examination

- Subcutaneous swelling
- Cough
- Vomiting
- Chronic kidney disease

## What differential diagnoses should be considered at this stage?

The subcutaneous swelling was crepitant which indicates trapped air beneath the skin (subcutaneous emphysema). The possible causes include:

- **Tracheal trauma:** air tracks between fascial planes in the soft tissues via discontinuity in the cervical or thoracic tracheal wall during respiration
- **Laryngeal trauma:** similar to tracheal trauma
- **Oesophageal trauma:** aerophagia may release air through a defect in the oesophageal wall
- **Pleural rupture:** external penetration through the thoracic wall and pleura (e.g. bite or bullet wound) may allow air to escape the lungs and spread into the soft

tissues; rib fracture may puncture the pleura without external penetration

- **Gas-producing bacteria:** subcutaneous pathogens associated with wounds or foreign bodies may produce gas that tracks between fascial planes as part of necrotizing fasciitis
- **Pneumatic tool introduction:** compressed air driven tools such as dental drills can force air into soft tissues beneath tooth roots
- **Barotrauma:** rupture of alveoli releases air which tracks through fascial planes

Gas-producing bacterial infection is less likely because the cat is normothermic, non-painful and bright. Air introduction via pneumatic tools is a differential for cervicofacial emphysema after human dental procedures, but this tends not to occur over the dorsal neck and shoulders.<sup>1</sup> Pleural rupture may be possible, but there is no history or clinical evidence of trauma.

Barotrauma may occur during anaesthesia when the pop-off valve is closed and pressures rise with the airways or when excessive positive-pressure ventilation is administered.<sup>2</sup> This cat had had a recent anaesthetic. A strong Valsalva manoeuvre in humans and reported in one cat<sup>3</sup> during excessive coughing or vomiting has also been linked to alveolar bursting and air tracking through fascial planes in the Macklin effect.<sup>4</sup> It is interesting to note the owner's report of dyspnoea following the one episode of vomiting since the dental procedure. Age is known to increase the risk of spontaneous airway rupture in humans, although this is usually paired with chronic obstructive pulmonary disease which is not found in this older cat.<sup>3</sup>

Vomiting may be an incidental occurrence linked to chronic kidney disease. It does however need to be differentiated from coughing up fluid by means of precise questioning of the owner, as this could indicate further pathology.

The causes that link coughing and subcutaneous emphysema are tracheal, laryngeal and oesophageal rupture. There is a potential for barotrauma although the large extent of the subcutaneous emphysema and timing makes this less likely.

## What initial investigations should be considered?

Radiographs of the neck, thorax and abdomen may be used to confirm the swelling as subcutaneous emphysema and map its extent. It may also help to identify the presence of air in other areas such as the pleura and mediastinum.

## Describe the radiographic changes seen in Figure 1

There is marked subcutaneous emphysema extending from the neck to the tail base, forelimbs, thorax and abdomen (red arrows). There is evidence of

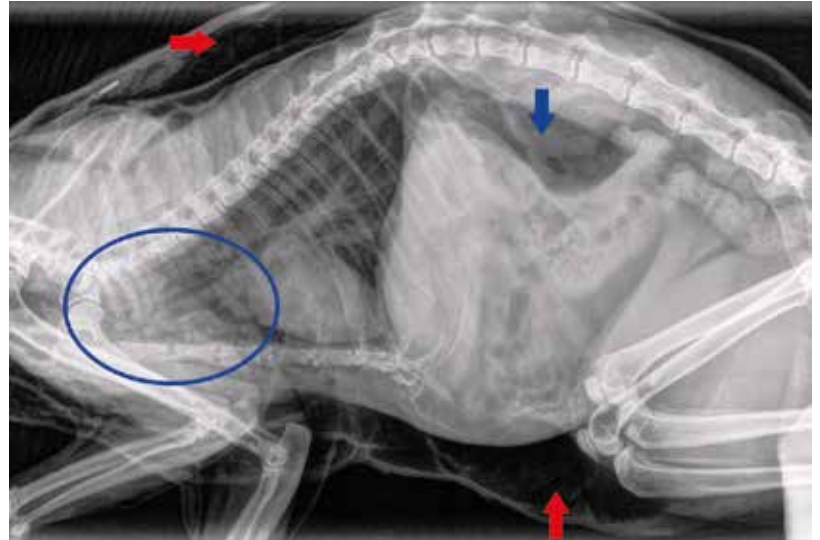


FIGURE 1: Conscious right lateral radiograph of thorax and abdomen.

pneumomediastinum as the cranial thoracic vasculature is well demarcated and both the dorsal and ventral portions of the tracheal wall are clearly demarcated (blue circle). There is air within the retroperitoneal space (pneumoretroperitoneum) (blue arrow). There is no evidence of pneumothorax. There is no evidence of rib fractures or foreign body.

## Create a revised differential diagnoses list for subcutaneous emphysema, pneumomediastinum, pneumoretroperitoneum and cough

Tracheal trauma is the most likely differential due to the large volume of gas accumulation. The fascial planes of the trachea connect with the mediastinum and retroperitoneum.<sup>2</sup> Laryngeal rupture may be considered as subsequent pneumomediastinum and pneumoretroperitoneum have been reported as sequelae of bite injuries in dogs,<sup>5</sup> but this is inconsistent with the history and clinical examination of this cat. Laryngeal damage that has not involved the trachea has not been shown to cause such marked air accumulation in cats.<sup>6</sup> Although spontaneous pneumomediastinum has been described in humans and cats following barotrauma<sup>4</sup> the large volume of gas in multiple locations makes this less likely. The large volume of air accumulation is not consistent with oesophageal rupture.

## What is the likely aetiology of tracheal trauma?

- Tracheal rupture of the dorsal ligament is associated with traumatic intubation, penetrating injuries, foreign bodies, traumatic tracheal wash and tracheobronchoscopy procedures<sup>2</sup>





- Tracheal avulsion is associated with blunt force trauma and hyperextension of the neck against a fixed carina (e.g. road accident). This extends circumferentially at the site of the intercartilaginous annular ligament<sup>4</sup>

No penetrating injuries can be identified externally or on radiographs. There is no history of tracheal procedures other than intubation for a dental. There is no history of trauma. Cats with circumferential tracheal avulsions often present with dyspnoea, which is not found in this cat.<sup>7</sup>

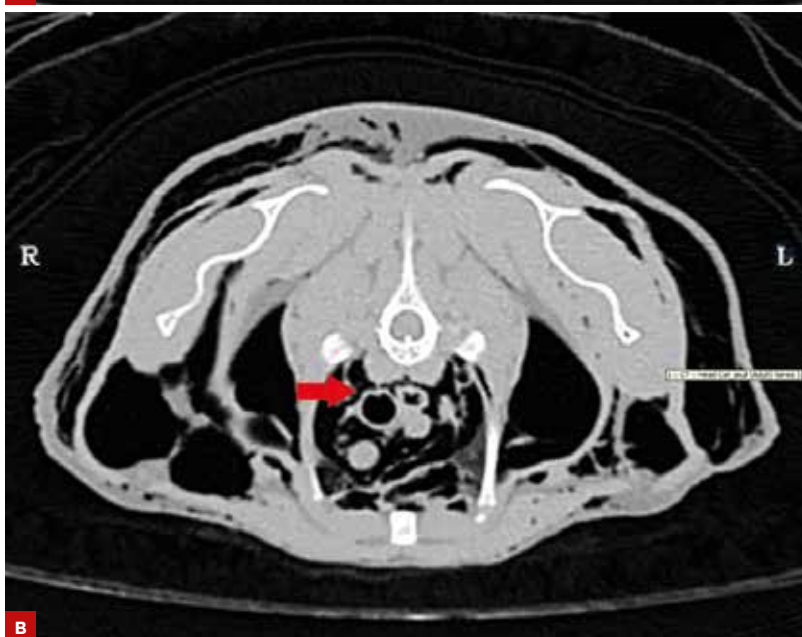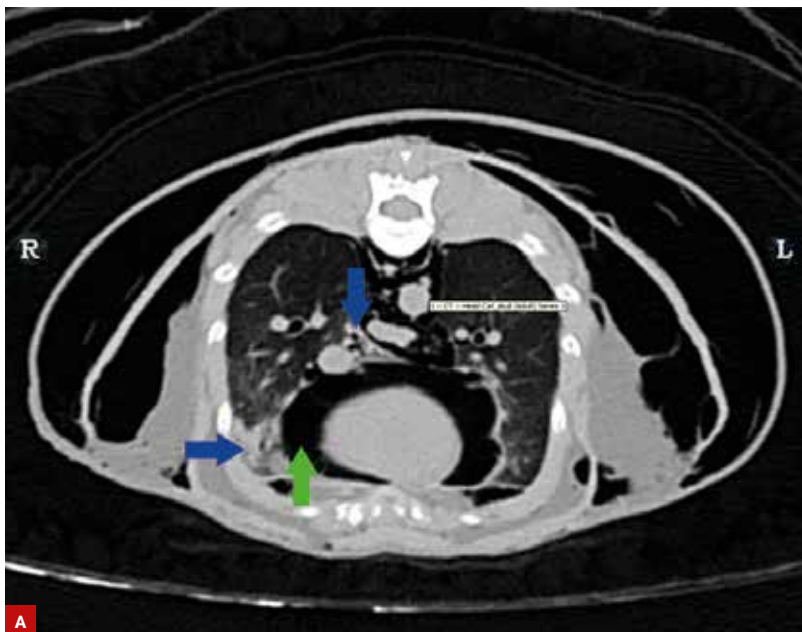


FIGURE 2: CT image of thorax at level of third rib.

## What further investigations may be useful at this stage?

The cat was referred for specialist imaging. There were a number of modalities considered.

- Computed tomography (CT) provides highly detailed images of defects in the larynx, trachea and bronchi with precise location regarding surrounding structures. The extent of gas accumulation within tissues may also be precisely mapped
- Tracheobronchoscopy allows direct visualization of the internal tracheobronchial wall
- Tracheobronchography via positive contrast imaging using an iodine-based agent such as iohexol may reveal the site of gas leakage
- Fluoroscopy may reveal the site of rupture if the defect is opened dynamically and therefore may not be seen on static images<sup>2</sup>

The first line considerations were CT and tracheobronchoscopy. CT was performed of her head, neck and thorax. It has been successfully used to identify tracheal rupture in cats and humans.<sup>8</sup> Tracheobronchoscopy has been used with varying success in cats, although a significant plane of anaesthesia must be achieved and the endoscope may worsen a rupture following introduction into the narrow feline trachea. It can be unsuccessful in diagnosing disruption location in cats – proposed reasons are the narrow feline trachea, operator error and tracheal membrane draping over defects. A tracheobronchogram or fluoroscopic investigation may be second line if the aetiology is not elucidated by other modalities. These may not be helpful when a cat is breathing calmly because mucus, fibrinous adhesions and blood clots can seal the defect against normal pressures.<sup>8</sup>

## Describe the additional changes seen on CT in Figure 2

There is air within the pericardial sac (pneumopericardium) (green arrow). There is no significant pneumothorax and the lungs parenchyma appears normal other than small regions of atelectasis affecting the ventral periphery and the accessory lobe adjacent to the mediastinum (blue arrows). There is no obvious disruption of the tracheal or bronchial walls. There is no obvious pseudotrachea wherein intact tracheal adventitia and thickening of mediastinal tissue maintains the airway lumen in place of wall disruption.<sup>7</sup> From the third to the fourth rib there is very slight irregularity of the dorsal margin of the trachea (red arrow). This may represent a defect or normal dorsal membrane infolding. There is no evidence of circumferential tracheal avulsion. No oesophageal lesion is identified.

The presumptive diagnosis is a tracheal rupture based on the history of cuffed intubation and clinical signs. A large proportion of cats treated conservatively for this condition with success have only had a presumptive diagnosis.<sup>9</sup>

### How would you manage this case?

The options are conservative treatment *versus* surgical intervention. Cats with non-progressive subcutaneous emphysema and mild to moderate dyspnoea that responds to oxygen supplementation may be considered candidates for conservative treatment. This cat had worsening subcutaneous emphysema and was considered for surgical correction but the site of rupture could not be found before the owner opted to have no further investigation.

The conservative management employed included needle drainage of subcutaneous emphysema and cage rest with mild sedation if required. This resolves clinical signs in up to 5 weeks with no recurrence in the majority of conservatively managed cats. Analgesia is often not required as although humans report retrosternal pain with pneumomediastinum, this has not been evidenced in cats.<sup>2</sup>

Oxygen supplementation has been used to induce 'nitrogen washout' in humans to hasten resolution of pneumomediastinum. Studies have shown efficacy in experimental cats but not in a clinical population.<sup>4</sup>

### What is the prognosis for this case?

The prognoses with both conservative management and surgical repair are good. Tracheal narrowing is an uncommon secondary development after presumed cuff damage and stenosis is more likely to occur after avulsion. This may take weeks to months to develop, so ongoing monitoring for inspiratory stridor and dyspnoea is warranted. The majority of cats discharged from hospital following conservative/surgical treatment are well at long-term follow-up.<sup>2</sup> Although a definitive diagnosis could not be reached in this cat, she responded well to conservative management with gradual resolution of air accumulation on subsequent radiographs 8 days post dental.

### Discussion

Tracheal rupture is an uncommon but recognized risk of using over-inflated cuffs on endotracheal tubes during anaesthesia. This is disproportionately seen following dental procedures, thought to be due to over-inflation of the cuff to protect the airway from fluid and because of twisting and manipulation of the head. In a study on cat cadavers, only excessive cuff inflation was associated with the typical injury seen in tracheal rupture, a linear left-sided rupture of the dorsal ligament. The extent of ruptures may be worse with high-volume low-pressure cuffs but rupture can occur with over inflation irrespective of cuff type.<sup>10</sup> This case may well have been prevented.

### How would you prevent this in future cases?

Use the largest diameter tube to seal the trachea with minimal cuff inflation (usually 3.5–4.5 mm). Tracheal palpation may aid appropriate size selection. Any cuff inflation should be performed in 0.5 ml increments not exceeding 3 ml total. Listening for air leaks while the reservoir bag is squeezed on a closed circuit after each increment is the most effective way (bar manometry) of preventing over inflation. Twisting of the trachea in cadavers has not been associated with the linear tears commonly seen with intubation trauma; however, disconnection from circuits prior to turning is recommended.<sup>10</sup> When protection of the airway from fluid is paramount pharyngeal gauze packing is preferred.<sup>9</sup> ■

### References

1. Fruhauf J *et al.* (2005) Soft Tissue Cervicofacial Emphysema After Dental Treatment. *Archives of Dermatology* **141**(11), 1437–1440
2. Holt D (2015) Tracheal Trauma. In: *Small Animal Critical Care Medicine, 2nd edition*, DC Silverstein and K Hopper, pp. 107–109. Elsevier Saunders, St Louis, Missouri, USA
3. Albaladejo J *et al.* (2012) Spontaneous Tracheal Laceration in a Cat with Asthma. *Journal of Feline Medicine and Surgery* **14**(9), 650–658
4. Thomas E *et al.* (2013) Pneumomediastinum in cats: 45 cases (2000–2010). *Journal of Veterinary Emergency and Critical Care* **23**(4), 429–435
5. Nikahval B *et al.* (2015) Generalized subcutaneous emphysema caused by concurrent cricoid cartilage fracture and cricotracheal detachment in a German Shepherd Dog. *Iranian Journal of Veterinary Research* **16**(2), 226–228
6. Hofmeister E *et al.* (2007) Traumatic endotracheal intubation in the cat. *Veterinary Anaesthesia and Analgesia* **34**, 213–216
7. Schmeirer A *et al.* (2014) Novel avulsion pattern of the left principal bronchus with involvement of the carina and caudal thoracic trachea in the cat. *Journal of Feline Medicine and Surgery* **16**(8), 695–698
8. Bhandal J *et al.* (2008) Tracheal rupture in a cat: Diagnosis by computer tomography. *The Canadian Veterinary Journal* **49**, 595–597
9. Mitchell S *et al.* (2000) Tracheal rupture associated with intubation in cats: 20 cases (1996–1998). *Journal of the American Veterinary Medical Association* **216**(10), 1592–1595
10. Hardie E *et al.* (1999) Tracheal rupture in cats: 16 cases (1983–1998). *Journal of the American Veterinary Medical Association* **214**(4), 508–512

# Clinical conundrum



*Matthew Smith of Nantwich Veterinary Group invites Companion readers to consider a lethargic English Springer Spaniel.*

**A**n 8-year-old female neutered English Springer Spaniel was presented with a 24-hour history of lethargy and reduced appetite. There was no history of vomiting, diarrhoea, coughing, lameness, collapse or known exposure to toxins. The dog had no previous medical problems reported.

Clinical examination revealed pale mucous membranes, a mild jaundice discoloration of the sclera, a capillary refill time of 1–2 seconds, a heart rate of 120 beats per minute, a respiratory rate of 28 breaths per minute and a temperature of 41.2°C. No cardiac murmur, arrhythmia or pulse abnormalities were noted. Lung-field auscultation and abdominal palpation were unremarkable. Palpable lymph nodes were normal and no joint effusions, lameness or spinal pain were detected. Neurological and orthopaedic examinations were unremarkable.

Further questioning revealed that the dog had returned to the UK from South West France, 9 days earlier. While abroad, a vet applied a topical imidocloprid and flumethrin collar 16 days prior to presentation, to treat the dog for a tick infestation.

**Create a problem list for this patient based on the history and clinical examination**

- Marked pyrexia
- Jaundiced sclera
- Pale mucous membranes
- Lethargy
- Reduced appetite

**What differential diagnoses should be considered for this problem list?**

## Pyrexia

The causes of pyrexia are extensive but some of the most common include:

- Infectious agents – bacterial, viral and parasitic
- Autoimmune diseases (e.g. immune-mediated haemolytic anaemia (IMHA) and steroid responsive meningitis)

- Allergic reaction (e.g. drug induced)
- Pain (e.g. pancreatitis).

## Jaundiced sclera

The mild jaundiced discoloration of the sclera indicates hyperbilirubinemia. Bilirubin is released into the circulation following haemolysis of erythrocytes. In a healthy animal the bilirubin is absorbed by hepatocytes and excreted with other bile constituents. Hyperbilirubinemia is therefore caused by:

- Pre-hepatic disease leading to haemolysis (e.g. IMHA)
- Hepatic disease (e.g. end-stage liver disease or leptospiral infection)
- Post-hepatic disease (e.g. biliary tract obstruction secondary to pancreatitis or a mass).

## Pale mucous membranes

This indicates the presence of either:

- Anaemia, or
- Poor peripheral circulation (e.g. cardiac disease, hypovolaemia etc).

Since the heart rate, peripheral pulses and capillary refill time were within normal limits it was likely that the pale mucous membranes were due to anaemia rather than poor peripheral circulation. Anaemia may have been a cause of the lethargy.

The lethargy and decreased appetite are non-specific signs that may be caused by the pyrexia but they may also be attributed to other abnormalities such as hepatic disease, renal disease, endocrinopathies and neoplasia.

**What initial investigations would you consider?**

The history and examination raised suspicion of anaemia or hepato-biliary disease with the pyrexia pointing towards an infectious or immune-mediated disease. The recent exposure to ticks and travel to France increased the suspicion of a possible vector-borne disease.

The initial tests consisted of:

- Haematology (Table 1) including examination of a fresh air-dried blood smear and packed cell volume (PCV) to look for evidence of anaemia, infectious and immune-mediated diseases
- Serum biochemistry (Table 2) to assess hepatic and renal parameters in particular
- Urinalysis (Table 3) to check specific gravity, protein, bilirubin and blood levels (in-house testing).

## How do these results refine your differential diagnoses?

The haematology results confirm the presence of a mild anaemia. The normal reticulocyte count suggested either a non-regenerative anaemia, or a pre-regenerative anaemia due to acute haemolysis or haemorrhage. There had been no history of haemorrhage, haematemesia, haematochezia or trauma. Acute haemorrhage was deemed to be unlikely as the clinical examination had revealed a normal heart rate, capillary refill time and pulse quality, with no evidence of petechial haemorrhage.

“ The haematology results confirm the presence of a mild anaemia. ”

The bilirubinaemia, reticulocyte count and erythrocyte inclusion bodies indicated a high likelihood of anaemia due to acute haemolysis following infection with an intracellular parasite. Immune-mediated haemolytic anaemia (IMHA) can be either primary or secondary due to an underlying trigger such as infectious agents (bacterial or parasitic), drugs (e.g. sulphonamides or cephalosporins), neoplasia and genetic predisposition. The recent history of tick exposure in South West France and the intracellular parasites led to a high suspicion of a *Babesia* infection. *Babesia canis* is spread by *Dermacentor reticularis* and is endemic in areas of Southern France. *Babesia* causes anaemia due to a combination of direct erythrocyte damage by the parasite, and both intravascular and extravascular immune-mediated haemolysis. Anti-erythrocyte antibodies have been implicated in cases of babesiosis, explaining the secondary immune-mediated haemolysis.<sup>1,3</sup> Spherocytosis has been reported in 89% of cases of primary IMHA.<sup>4</sup> The lack of spherocytes in this case made primary IMHA a less likely differential diagnosis but could not exclude it completely.

Haematology revealed a leucopenia and a thrombocytopenia. The potential causes of leucopenia and thrombocytopenia are extensive but they are commonly seen following infection with intracellular parasites such as *Babesia*. The reason for the thrombocytopenia is poorly understood but local and systemic disseminated intravascular coagulation (DIC), immune-mediated destruction and sequestration of platelets have been suggested.

The raised alanine aminotransferase (ALT) and alkaline phosphatase (ALKP) levels indicated that there had been recent hepatocellular damage. The cause could not be identified at that stage but it is a common finding in cases of babesiosis, especially those with marked icterus.



Parameter	Result	Reference range
Haematocrit (HCT) (L/L)	<b>0.326</b>	<b>0.380–0.570</b>
Red cell count (RCC) ( $\times 10^{12}/L$ )	<b>4.64</b>	<b>5.50–8.50</b>
Haemoglobin (HGB) (g/dL)	<b>11.5</b>	<b>12.0–18.0</b>
Mean cell volume (MCV) (L)	74.6	61.0–80.0
Mean cell haemoglobin concentration (MCHC) (g/dL)	33.2	30.0–36.0
Absolute reticulocyte count ( $\times 10^{12}/L$ )	37.6	$\leq 140.0$
White blood cell count (WBC) ( $\times 10^9/L$ )	<b>3.1</b>	<b>6.0–15.0</b>
Lymphocytes ( $\times 10^9/L$ )	<b>0.19</b>	<b>0.5–4.8</b>
Monocytes ( $\times 10^9/L$ )	0.16	$\leq 0.80$
Neutrophils ( $\times 10^9/L$ )	2.73	2.50–12.50
Eosinophils ( $\times 10^9/L$ )	0.03	0.00–0.80
Platelets ( $\times 10^9/L$ )	<b>123</b>	<b>175–500</b>
Packed cell volume (PCV) (%)	<b>30</b>	<b>38–56</b>

TABLE 1: Haematology results from the day of admission. In-house microscopic examination of the air-dry smears revealed what appeared to be intracellular erythrocyte lesions. No spherocytes were observed (abnormal results in bold).

Parameter	Result	Reference range
Albumin (g/L)	27.0	23–40
Alkaline phosphatase (ALKP) (IU/L)	<b>415</b>	<b>23–212</b>
Alanine aminotransferase (ALT) (IU/L)	<b>457</b>	<b>10–100</b>
Amylase (IU/L)	708	500–1500
Lipase (IU/L)	312	200–1800
Urea (mmol/L)	4.2	2.5–9.6
Creatinine ( $\mu\text{mol}/L$ )	91.00	44–159
Phosphorous (mmol/L)	1.19	0.81–2.20
Calcium (mmol/L)	2.15	1.98–3.00
Glucose (mmol/L)	5.73	4.11–7.95
Globulin (g/L)	36	25–45
Total protein (g/L)	63	52–82
Total bilirubin ( $\mu\text{mol}/L$ )	<b>22</b>	<b>0–15</b>
Sodium (mmol/L)	152	144–160
Potassium (mmol/L)	4.2	3.5–5.8
Chloride (mmol/L)	117	109–122

TABLE 2: Serum biochemistry results from the day of admission (abnormal results in bold).

Parameter	Result	Reference range	Test range
Bilirubin	<b>4+</b>	<b>Negative</b>	<b>Negative–4+</b>
Blood	<b>4+</b>	<b>Negative</b>	<b>Negative–4+</b>
Protein	<b>3+</b>	<b>Negative</b>	<b>Negative–4+</b>
pH	8		5–9
Specific gravity	> 1.050		1.000–1.050

TABLE 3: Urinalysis results from the day of admission (abnormal results in bold).



Urinalysis confirmed the presence of bilirubinuria, haematuria and proteinuria. All three of these could be caused by haemolysis due to an IMHA. The haematuria was considered more likely to be a cross reaction of the urine stick test to haemoglobinuria rather than genuine haematuria. With hindsight, a urine sediment examination would have been useful, as a lack of red blood cells would have supported the suspicion of haemoglobinuria.

Clinical signs of babesiosis include lethargy, weakness, pyrexia, anorexia, pale mucous membranes, icterus and dark discoloration of urine. Laboratory features of babesiosis include anaemia (usually regenerative, but it may be pre-regenerative in acute cases), thrombocytopenia, variable leucocyte abnormalities, haemoglobinuria, bilirubinuria, and mild to moderate increases in ALT, ALKP and bilirubin.<sup>1,2,5</sup> All of the clinical findings and initial results for this case could be attributed to babesiosis.

### What further investigations may be helpful at this stage?

The high suspicion of babesiosis led to fresh blood smears and blood samples being sent to an external laboratory for cytology and polymerase chain reaction (PCR) tests, for organisms transmitted by arthropod vectors. Given the recent travel history, a PCR testing package was selected that tested for *Babesia*, *Borrelia*, *Ehrlichia* and *Leishmania*. Concurrent vector-borne diseases, especially ehrlichiosis, are often seen in conjunction with babesiosis.<sup>2,3</sup>

Auto-agglutination of erythrocytes was confirmed on an in-house saline agglutination test. This again pointed towards an IMHA but it could not be used to identify the underlying cause. Positive saline agglutination tests occur in over 20% of babesiosis cases.<sup>2,3,5,6</sup>

Abdominal ultrasonography was performed, with particular attention being paid to the liver and spleen, to look for lesions that could explain the raised hepatic

parameters or trigger an IMHA (e.g. neoplasia). Although babesiosis was the most likely differential diagnosis, other causes of IMHA could not be excluded at this stage.

### Results

No abnormalities were noted on ultrasound examination. The external laboratory haematology and fresh blood smear examination revealed normocytic, normochromic erythrocytes. Occasional red blood cell parasites were noted. The parasites were large, ring/pyriform bodies occasionally in pairs and were consistent with *Babesia canis* (Figure 1). Platelets appeared plentiful with frequent clumps.

*Babesia canis* was confirmed on PCR as the cause of the anaemia. The PCR results for *Borrelia*, *Ehrlichia* and *Leishmania* were all negative.

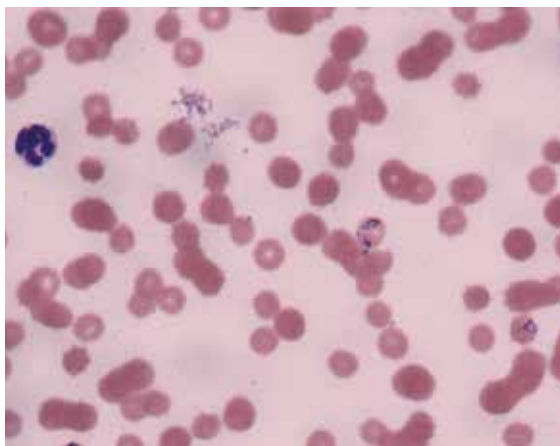
### How would you treat this case?

Pyrexia of 41.2°C on presentation was initially the most concerning finding; if left untreated, pyrexia can cause dehydration, shock and permanent organ damage, including brain damage.

Intravenous fluid therapy with Hartmann's solution was started after the haematology and serum biochemistry samples had been collected. Fluids were administered at 2 mL/kg/h as there was no evidence of dehydration, and higher fluid rates may have had detrimental effects on the PCV due to haemodilution. The temperature dropped quickly and was normal 2 hours later. Treatment for babesiosis was not given until the in-house cytological finding of intracellular erythrocyte parasites had been confirmed by a specialist pathologist. In the meantime, doxycycline (10 mg/kg orally q24h) was started in case of concurrent ehrlichiosis.

The external haematology and fresh smear analysis were received the following day. At this point, treatment was started with imidocarb dipropionate (6.6 mg/kg subcutaneously), which has been shown to be effective in the treatment of *Babesia canis*. Imidocarb dipropionate has not been licensed for use in dogs in the UK but, as it is licensed for the treatment of babesiosis in cattle in the UK and dogs in the USA, this is considered to be the most appropriate product under cascade. The dog was kept under observation for a further 24 hours to monitor the PCV and potential adverse reactions. The following day, the PCV was stable at 28%, the temperature was 38.3°C, the dog was bright, eating well, and discharged from the hospital. The PCV was checked over the following 4 weeks (Table 4). Doxycycline was withdrawn after 6 days of treatment following the negative PCR results for *Ehrlichia canis* and *Borrelia burgdorferi*. Imidocarb dipropionate treatment was repeated 14 days after the first injection.

Two weeks after the second injection of imidocarb dipropionate, blood samples were taken to repeat the *Babesia* PCR and serum biochemistry. The PCR was negative indicating that no further imidocarb



**FIGURE 1:** Image of the blood smear showing intracellular *Babesia canis* organisms.

(Image courtesy of Elizabeth Villiers, DWR Diagnostics)


Day	Packed cell volume (%)
0 (admission)	30
1 (1st imidocarb dipropionate injection)	27
2 (discharge)	28
5	30
9	33
15 (2nd imidocarb dipropionate injection)	38
30	43

TABLE 4: Packed cell volume (PCV) figures during treatment.

dipropionate treatment was required. The serum biochemistry results were all within normal limits.

The dog in this case made a full recovery. The efficacy of treatment and prognosis for *Babesia canis* tends to be more favourable compared with that of *Babesia Gibsoni*, which is also present in mainland Europe. The owner was advised that complete elimination of the parasite could not be guaranteed and the dog could remain a potential reservoir for infection.<sup>2</sup> The owner was advised to keep the dog up-to-date with acaricide treatment.

The severity of clinical signs in cases of canine babesiosis vary hugely, from relatively mild anaemia through to severe cases with marked haemolytic anaemia, acute renal failure, multiple organ failure and rarely, respiratory distress syndrome. In cases with severe anaemia or a rapidly decreasing PCV, whole blood or packed red cell transfusions should be considered. The anaemia in this dog was not severe enough to require a transfusion. Immunosuppression with corticosteroids has been advocated by some authors for treatment of severe immune-mediated haemolysis but this is a controversial recommendation due to the underlying infectious agent. Corticosteroids were not considered appropriate in this case.

This case was seen 4 years prior to the discovery of *Babesia* within the United Kingdom tick population and reported cases of babesiosis in untravelling dogs. With the relaxation of the EU Pet Travel Scheme requirements regarding tick treatment prior to entry to the United Kingdom, this case highlights the need for general practitioners to consider potential exotic vector-borne diseases in all animals regardless of their travel history. 



References and further reading are available online and in *e-Companion*.

# Submit a Clinical Conundrum

With the Clinical Conundrum we hope to offer accessible, thought-provoking CPD for the reader and to allow some in-depth discussion of the intricacies of the case presented. In particular it is hoped that cases will challenge the reader to consider a dilemma, be it a diagnostic challenge or a treatment/surgical decision, and to work through it to a logical conclusion.

The aim of the Clinical Conundrum is to present clinical scenarios that are encountered in small animal practice and discuss briefly any particularly important features of the case. The Clinical Conundrum can focus on the complete case management or one aspect of the case management in more detail.

An unusual diagnosis does not necessarily mean that a case will be suitable to present as a Clinical Conundrum. In fact, the final diagnosis is not the most important part of the feature. Indeed, the cases that make the best Clinical Conundrums discuss a presentation thoroughly, logically progress through a case and achieve a robust diagnosis or treatment choice. It is the dilemma regarding diagnostic or treatment progression that is important rather than the final diagnosis in and of itself.

The editorial team is more than happy to advise potential authors and particularly encourage submissions from those in general practice.

Authors should aim for a piece of 1400–2000 words in length with 1–5 illustrative pictures. Given that the emphasis of this feature is problem solving, references are not usually required unless specific literature is mentioned or their use is needed to support the approach taken. We are particularly keen to have submissions that have additional video content for use with our digital versions of *Companion*.

An honorarium is payable on final acceptance of the article. If you have an idea for a Clinical Conundrum, please contact us at [companion@bsava.com](mailto:companion@bsava.com) and access the full submission guidelines online at [www.bsava.com](http://www.bsava.com).